

Assessment Of Ponseti Method For The Treatment Of Congenital Idiopathic Clubfoot- A Descriptive Cross-Sectional Study

Md. Mohiuddin Aslam¹, Malay Kumar Saha²

¹Assistant Professor, Department of Orthopaedic Surgery, Shaheed Ziaur Rahman Rahman Medical College, Bogura, Bangladesh

¹Associate Professor, Unit Chief, Department Of Orthopaedic Surgery, MBBS, D-Ortho, MS-Ortho, Mymensingh Medical College, Mymensingh, Bangladesh

Corresponding Author: Md. Mohiuddin Aslam
Assistant Professor, Department of Orthopaedic Surgery,
Shaheed Ziaur Rahman Rahman Medical College,
Bogura, Bangladesh
Email: koushik.ortho73@gmail.com

Abstract

Introduction: Clubfoot, or talipes equinovarus, is a congenital deformity consisting of cavus, forefoot adduction, heel varus, ankle equinus and internal tibial torsion. Unilateral clubfoot is somewhat more common than bilateral clubfoot and may occur as an isolated defect or in association with other disorders (eg, chromosomal aberrations, cerebral palsy, spina bifida, arthrogryposis). **Objective:** Our study aim was to evaluate Ponseti Method for the treatment of congenital idiopathic clubfoot. **Materials and Methods:** This was a descriptive cross-sectional study conducted in the Department of Orthopaedic Surgery, Shaheed Ziaur Rahman Rahman Medical College, Bogura, Bangladesh during the period from January 2020 to Jun 2020. Data was collected from patients with idiopathic clubfoot, presenting at selected hospital. Both, unilateral, bilateral were included in the study. **Results:** In this study, we have treated 46 children with idiopathic clubfoot by Ponseti Method of correction of serial manipulation and casting. Among the 46 children, 24 had unilateral and 22 bilateral involvement. Male were 26 and remaining 20 were female. Most children had grade III and grade IV (Dimeglio et al grading) deformity. The mean number of casts required was 5.66 (4 to 10). Tenotomy was required for 17 patients (37%). The scores for the entire group ranged from 4.0 to 7.0 (of 18) and 4 to 19 (of 28) in the Dimeglio classification. Pirani scores for the age group 0- 6 months were 4.44, 6 months to 1 year were 5.28 and 1-2 years were 5.64 respectively. The results were excellent in 36 (82%), good in 7 (15%) and inefficient in 3 (6.52%). Initial and final scores were statistically evaluated with paired „T“ test with a „T“ value of 37.13 with a „P“ value of less than 0.001. Thus there was a significant reduction in the score from the pre level because of intervention. Similar good results and low requirement for surgical interventions other than Achilles tenotomy, which forms part of the Ponseti regimen, were found. In terms of number of patients the success rate is

93.5% and in terms of the number of feet the success rate is 94%. **Conclusion:** This study demonstrates that treatment of congenital talipes equine varus by conservative management of Ponseti Method can considered as one of the most effective treatment method.

Keywords: Clubfoot, Ponseti Method, Foot Deformities, Congenital.

I Introduction

The foot points down and inwards and the soles of the feet face each other. It is known as talipes equinovarus (TEV) or congenital talipes equinovarus (CTEV) [1]. In the study we found in 22 (48%) of cases, both feet were affected. On the other hand 24 cases were unilateral. Clubfoot is a birth defect that is marked primarily by a deformed talus (ie, ankle) and calcaneus (ie, heel) that give the foot a characteristic "club-like" appearance. In congenital idiopathic clubfoot (ie, talipes equinovarus), the infant's foot points downward (ie, equinus) and turns inward (ie, varus), while the forefoot curls toward the heel (ie, adduction). The term talipes is derived from Latin talus-ankle, and pes-foot [2]. The term refers to the gait of severely affected patients, who walked on their ankles. The goal of treatment is to correct all components of the deformity so that the patient has a pain-free plantigrade foot with good mobility, without calluses, and without the need to wear special or modified shoes. In 1889, L.H. Bradford has been quoted as saying. "The literature on the treatment of clubfoot is, as a general rule, that of unvarying success. It is often as brilliant as an advertising sheet and yet in practice there is no lack of half-cured or relapses cases, sufficient evidence that method of cure are not universally understood. More than a hundred years on, these words, unfortunately, still ring true. Treatment is ideally started soon after birth by passive manipulations which are taught to the parents till casting is started after 7-10 days. The first element of management is correction of the cavus deformity by

positioning the forefoot in proper alignment with the hindfoot [3]. The manipulation consists of abduction of the foot beneath the stabilized taller head. Locate the head of the talus. All components of clubfoot deformity, except for the ankle equinus, are corrected simultaneously. To gain this correction, one must locate the head of the talus, which is the fulcrum for correction. During this phase of treatment, the adductus and varus are corrected. The distance between the medial malleolus and the tuberosity of the navicular when palpated with the fingers tells the degree of correction of the navicular. When the clubfoot is corrected, that distance measures approximately 1.5 to 2cm and the navicular covers the anterior surface of the head of the talus [4]. Similarly, the extent of the lateral displacement of the anterior tuberosity of the calcaneus under the head of the talus indicates the increase in value of the talo-calcaneal angle, and thus, the degree of correction of the heel varus. The equinus deformity gradually improves with correction of adductus and varus. This is the part of correction because the calcaneus dorsiflexes as it abducts under the talus. No direct attempt at the equinus correction is made until the heel varus is corrected. In very flexible feet, equinus may be corrected by additional casting without tenotomy. When in doubt, perform the tenotomy. Success in Ponseti management requires good casting technique. Those with previous club foot casting experience may find it easier than those learning clubfoot casting for the first time. The endpoint was a score less than 1.5 with the feet having 70 degrees of external rotation and 15 degree of dorsiflexion. In that study the parents of the patients were advised to preserve the plaster casts as they served as replica for assessing the correction. The duration was set according to the tradition of the most intervention performed in the globe and found most effective as well as justified.

II Objectives

1. General Objective

a) To evaluate Ponseti Method for the treatment of congenital idiopathic clubfoot.

2. Specific Objectives:

a) To know more about the pattern congenital idiopathic clubfoot in Bangladesh.

b) To know more about the treatment options of congenital idiopathic clubfoot.

III Materials and Methods

This was a descriptive cross-sectional study was conducted in the Department of Orthopaedic Surgery, Shaheed Ziaur Rahman Rahman Medical College, Bogura, Bangladesh during the period from January 2020 to Jun 2020. The aim of the study was to assess Ponseti Method for the treatment of congenital idiopathic clubfoot. We had used the pirani severity scoring 3 developed by Catterall and Shafique pirani to evaluate the correction in an unoperated congenital

clubfoot less than 2 year of age. This rating has proved its efficacy in having little inter and intra-observer variability. Documenting the amount of deformity allows the treating practitioner where he or she is with respect to the road map of treatment, to know when tenotomy is indicated, and to reassure parents regarding progress. It allows meaningful comparison of results, extractions of subgroups, etc. We used three scores to clear the clinical signs of the patients. To indicate normal, moderately normal and severely abnormal signs we used the score as „0“, „0.5“ and „1“ respectively. As Midfoot Score we used a grading from 0 to 3 and there the considering major deformities were A: Curved lateral border, B: Medial crease and C: Talar head coverage. On the other hand as Hindfoot Score we used a grading from 0 to 3 and there the considering major deformities were D: Posterior crease, E: Rigid equines and F: Empty heel. There was a schedule for the total treatment period. During first Two (2) weeks for each patient we troubleshoot on compliance issues. Next three months we ensured graduation to nights-and-naps protocol. Besides that in every four (4) months until the patient's age gone to three years we monitored the compliance as well as relapses issues. In every six months until the patient's age gone to 4 years we monitored the reorder or cancellation issues. Lastly at the end of the intervention we ensured the skeletal maturity of the patients. Where the child was above one year of age, he/she put on clubfoot shoes. Those characteristically were an ankle foot orthoses, with a straight medial border, lateral wedge, no heel and an ankle strap with a gap at the point of heel to monitor the correct dorsiflexed position of the ankle through the shoes. The Dennis brown splint was worn at night for 4 hours. Whenever it was possible slight manipulations were done by parents. We were successful to ensure full participation of the respective parents which was very effective thing in the study.

IV Results

It was a descriptive cross-sectional study in the Department of Orthopaedic Surgery, Shaheed Ziaur Rahman Rahman Medical College, Bogura, Bangladesh during the period from January 2020 to Jun 2020. Our aim was to evaluate Ponseti Method for the treatment of congenital idiopathic clubfoot. There were altogether 46 patients included in the study. Male were 26 and remaining 20 were female [Figure-1]. Among the total patients 24 had unilateral and 22 bilateral involvement. In unilateral involvement, 20 right and only 4 left feet were found involved. So the bilateral ratio was 48% and total affected feet was 68 in number [Table-1]. We had considered some variables in the study. Such as, age of the patient, previous treatment and type of treatment before referral, number of casts required, need of percutaneous tendoachilles tenotomy and compliance with the foot abduction brace. The initial pirani score ranged from 5 to 6 and the number of casts ranged was from 6 - 8. Most of the patients had above-knee casts. Throughout the course of plaster treatment

special care was taken to counsel the parents regarding their role in watching for vascular and other plaster related complications. Clubfoot correction was obtained in all patients. Only a few patients had too severe a deformity that evaded correction. The end-point of correction was defined to be achieved if the feet had a score less than 1.5 with full correction of equinus. Number of Casts Correction was obtained with 6-8 casts. Only 68% feet required 6 casts for correction. The last cast was usually left on for 2 weeks if a tendoachilles tenotomy was done. 18% feet required 8 casts for correction and this was indicated because of minor complications and the severity of the deformity. This corroborates with the world literature where ponseti's method usually achieves plaster correction with 5 or 6 casts. Duration The average time from the first cast to the tendoachilles tenotomy/full correction of the deformity was 7 weeks. The parent compliance with the bracing protocol was remarkable. They were sounded as to their role in maintaining the correction with proper fitting shoes and changing the shoe size as the feet grew. All patients have had Percutaneous Tenotomy. We had a patient population less than 12 months of age with an average of less than One month and all the feet responded well to the technique protocol. Average post tenotomy ankle dorsiflexion was 15 degrees. A minimum follow-up of 12 months was possible with all the patients. The majority of patients started walking at the age of 16-18 months. In total 32 patients were followed up for 12 months and 14 patients up to 16-18 months within the timespan of the study. Strict concordance to the protocol for follow-up outlined by ponseti was maintained throughout the study. At each

follow-up the feet were evaluated for any early sign of relapse. Three (3) patients had an average final score of within 2. We found the reason for failure in those patients could be attributed to defective casting technique. Only 17 patients out of 46 had minor complications [Table-2 & 3]. All the complications were due to defective plastering technique and were unique to initial patients. In terms of number of patients the success rate is 93.5%. This was a great success of that intervention. In the study the results we found the effectiveness of Ponseti Method in treating congenital idiopathic clubfoot were excellent in 36 (82%), good in 7 (15%) and inefficient in 3 (6.52%) [Figure-2].

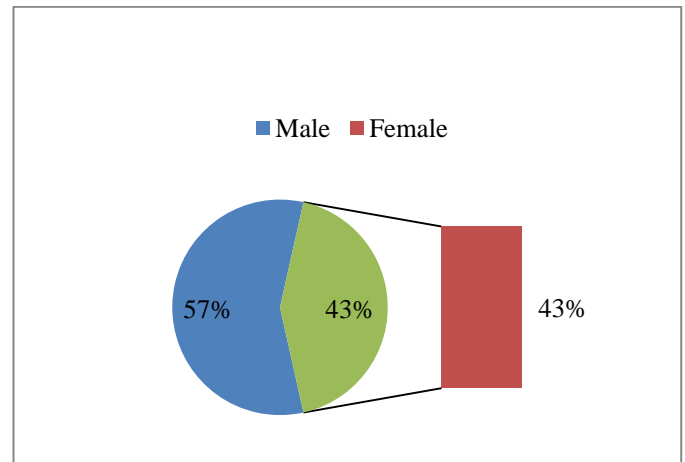


Figure-1: Male-female ratio of the patients (n=46)

Table-1: Side (feet) involvement of the participants (n=46)

Type	N	Right	Left	Total
Unilateral	24	20	4	68
Bilateral	22	22	22	
Total	46	42	26	

Table-2: Slandered deviation of total procedure (n=46)

Scoring	N	Mea	SD	Minimum	Maximum
Pirani scoring Baseline	46	5.58	0.42	5	6
Pirani scoring- Final	46	0.37	0.63	0.00	2.25

Table-3: Cohort analysis during the study (n=46)

Period	Min-Max	Mean ± SD	Difference from starting	p value
Starting	5-6	5.72±0.28	NA	NA
1st week	4-5.5	4.66±0.88	1	0.001
2nd week	3-5	3.53±1.28	1.5	0.001
3rd week	2-4.5	2.84±1.46	2	0.001
4th week	1-4.1	1.69±1.74	2.5	0.001
5th week	0-3.5	1.03±1.01	2.5	0.001
6th week	0-3	0.96±1.65	3	0.001
7th week	0-2.5	0.87±1.22	3.5	0.001
8th week	0-2.5	0.58±0.42	3.5	0.001
Final stage	0-2.5	0.37±0.63	3.5	0.001

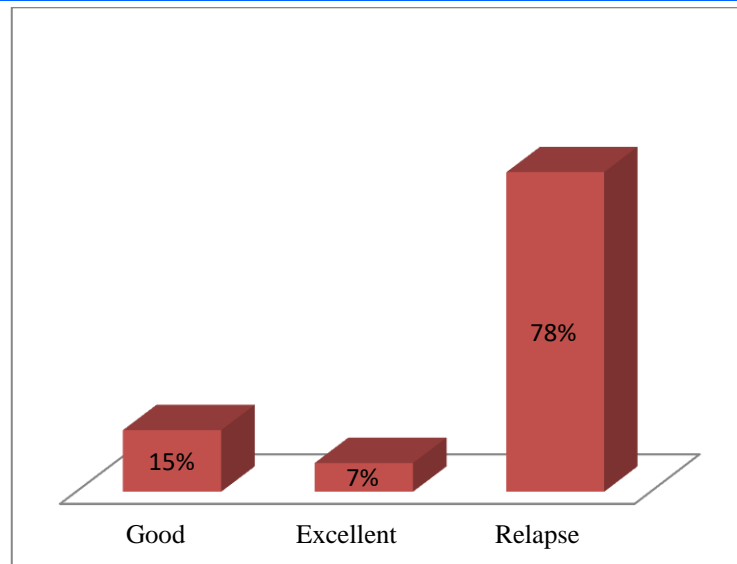


Figure-2: Success ratio of Ponseti Method (n=46)

V Discussion

This was a descriptive cross-sectional study in the Department of Orthopaedic Surgery, Shaheed Ziaur Rahman Rahman Medical College, Bogura, Bangladesh during the period from January 2020 to Jun 2020. Hence in this study, as there were only 3 patients out of 46 patients who had failure, ponseti method was a success [4, 5, 6]. A conservative method of management of idiopathic CTEV has been recommended by most Paediatric Orthopedicians in the early days of infancy starting as early as possible after birth. There have been many conservative protocols of management for idiopathic CTEV deformity. Traditional [7], Kite [8] and Ponseti methods are among the commonly used protocol treatment methods. In the recent years the Ponseti method is the most advocated method of the conservative management of idiopathic CTEV deformity. Several studies have been conducted to prove its efficacy [9]. After serial manipulation and cast treatment the maintenance of correction is an important issue. Various foot abduction orthoses such as Dennis Brown splint [10], Stenbek Foot abduction orthoses and Dobb's brace have been suggested as essential orthotic management for the prevention of recurrence. We, in our study evaluated the effectiveness of Ponseti casting as a mode of correction and maintenance of idiopathic CTEV deformity. There were altogether 46 patients with 68 feet included in the study. We evaluated the following variables. Age of the patient at first visit to our institution, previous treatment and type of treatment before referral, Number of casts, number of casts required at our institution, Need for percutaneous tendoachilles tenotomy and compliance with the foot –abduction brace. These variables were in turn related to the need for corrective surgery and the incidence of relapses. Fisher exact tests, t tests, and odds ratio were used as appropriate. The following are the outstanding bio statistical data derived from the study. A total of 26 (57%) patients were male, Kite in his

series of 1509 cases has reported 70% males and 30% females [11]. In Turcos [12] series of 468 patients there were 334 (71.36%) males and 134 (28.63%) females a sex ratio of 2.5:1; Male: Female. 24 patients had unilateral feet and thus unilateral feet exceeded bilateral feet in this study. Of the unilateral feet 20 were right and 4 left, Chung [13], observed a 50% bilaterality. Turcos series of 468 pts. Had 56% bilateral, 22% right and 21% left side involvement. At initial ponseti casting, all patients were younger than 12 months of age. The initial ponseti core ranged from 5 – 6. A total of 20 patients had some form of treatment before their initial visit to our institution. All the twenty had serial manipulation and casting done elsewhere. The number of casts ranged from 2 – 10. Stephen MD has reported an average of 2.5 months of treatment in his series of 37 patients. About fifty percent of these patients had below –knee casts and the rest had above-knee casts. All came to our hospital with all of the components of the deformity uncorrected. Throughout the course of plaster treatment special care was taken to counsel the parents regarding their role in watching for vascular and other plaster related complications. This counseling was effective and on several occasions the parents had contacted over phone from distant places and adequate advice could be given. In the study, we found the effectiveness of Ponseti Method in treating congenital idiopathic clubfoot were excellent in 36 (82%), good in 7 (15%) and inefficient in 3 (6.52%).

VI Limitations Of The Study

As it was a single center study with a small sample size and the success of this treatment method directly depends upon the co-operation of the patient's parents so these findings should not be generalized for the whole country and for the every situation.

VII Conclusion and Recommendations

It can be rightly concluded from our study that, Ponseti Method is a patient friendly and economically compliant method of easy and early correction of the club foot deformity. It is based on a strong scientific understanding of what the deformity is due to and what it is made up of. The results of our study closely match that available in literature which is an evidence of reproducibility of the correction irrespective of individual variations. All that is required is adherence to the basic principles outlined by the founder of the method. There is a limited but important learning curve for perfecting the method which is crucial to pass through to avoid basic errors as outlined by Ponseti as committable.

References:

1. Birth Defects Res A Clin Mol Teratol. 2009 Nov; 85 (11):897-904. doi: 10.1002/bdra.20625. Multistate study of the epidemiology of clubfoot.
2. Ponseti. Ponseti IV. Treatment of congenital clubfoot. J Bone Joint Surg. 1992; 74A:448.
3. Pirani, Pirani S, Outerbridge H, Moran M, et al. A method of evaluating the virgin clubfoot with substantial interobserver reliability. Presented at the annual meeting of the Pediatric Orthopaedic Society of North America, Miami, Fla, 1995.
4. Vesely DC. A method of application of a clubfoot cast. Clin Orthop. 1972; 84:47-49.
5. Karski T, Wogko 1. Experience in the conservative treatment of congenital clubfoot in newborns and infants. J Pediatr Orthop. 1989; 9:134-136.
6. Colburn M, Williams M. Evaluation of the treatment of idiopathic clubfoot by using the Ponseti method. J Foot Ankle Surg. 2003; 42(5):259-67.
7. Herzenberg JE, Radler C, Bor N. Ponseti versus traditional methods of casting for idiopathic clubfoot J Pediatric Orthop B. 2003; 12:133-140.
8. Kite JH. The clubfoot. London: William (Heinmann) Medical Books Ltd, 1964.
9. Staheli Clubfoot L. Ponseti management 3rd ed, Seattle, Washington: Global Help Publications, 2009.
10. Hattori T, Ono Y, Kitakoji T, Iwata H. Effect of the Dennis Browne splint in conservative treatment of congenital clubfoot J Pediatric Orthop B. 2003; 12:59-62.
11. Kite JH Principles in the treatment of congenital clubfoot J. Bone Joint Surgery. 1939; 21:595-606.
12. Turco VJ. Resistant congenital clubfoot American Academy of Orthopedic Surgeons Instructional Course Lectures, St Louis the CV Mosby Co. 1975; 24.
13. Chung CS, Nemechek RW, Larsen IJ, Chung GHS. Genetic and epidemiological studies of clubfoot in Hawaii Human Heredity. 1969; 19:321.