

Decompressive Craniectomy With Hematoma Evacuation For Management Of Deep- Seated Basal Ganglia Hemorrhage At The Era Of Minimal Invasive Endoscopic Surgery: Three Case Reports With Short Literature Review

Mohan Karki^{1,2}, MBBS, MS (Neurosurgery)

Yam Bahadur Roka¹, MBBS, MS, M.Ch (Neurosurgery)

¹ Department of Neurosurgery, Neuro Cardio and Multispeciality Hospital, Biratnagar, Nepal

²Corresponding Author

Dr. Mohan Karki

Consultant Neurosurgeon

Jahada Road-Biratnagar 56610, Morang, Nepal

jigyasu86@gmail.com

Contact number: +977-9816731172

ABSTRACT

Introduction: Deep-seated basal ganglia hemorrhage is major health issue with high morbidity, high mortality and higher rate of disability. The purpose of this study is investigate the role of decompressive craniectomy adding duraplasty and intracerebral hemorrhage evacuation for management of deep –seated basal ganglia hemorrhage.

Material and Methods: This study retrospectively analyzed the data of three cases of right deep-seated basal ganglia (BG) hemorrhage who received treatment in the hospital from January 2019 to December 2010. One of three cases had history of road traffic accident and two cases had history of hypertension. All three cases had GCS<8, midline shift with B/L pupil non-reactive before surgery. Decompressive craniectomy adding duraplasty along with ICH evacuation was applied for all three cases. Outcome was defined by Glasgow coma scale (GCS) at the time of discharge.

Results: All three cases had improvement in GCS and power after decompressive craniectomy adding GP duraplasty and ICH evacuation

Conclusion: Decompressive craniectomy adding duraplasty along with ICH evacuation during management for both TICH and HICH is effective and safe approach; and has better outcome (GCS-15/15) in all three patients.

Keywords—*Decompressive craniectomy, evacuation, traumatic, hypertensive, intracerebral hemorrhage, basal ganglia*

INTRODUCTION

Intracerebral hemorrhage (ICH) is a world widely devastating neurological problem. Intracerebral hemorrhage accounts for approximately 10-20 % of all stroke¹, and TICH is >40% of all head injuries². Systematic arterial hypertensive, cerebral amyloid angiopathy, alcohol consumption, smoking and diabetes are major risk factors for ICH^{3, 4}. Spontaneous or traumatic rupture of small penetrating or non penetrating vessels inside the brain parenchyma leads to accumulation of blood which may manifest expansive range of clinical and radiological symptoms depending on site and size of hemorrhage. Commonly, ICH can be divided into basal ganglia and lobar hemorrhage (including frontal, parietal, temporal and occipital). Patients suffering from a traumatic ICH (TICH) tend to be younger than those suffering from a hypertensive ICH (HICH), and more likely to be lobar, superficial and medium sized volume⁵.

The endoscope assisted keyhole technique is a minimally invasive surgical technique, and became new trend in neurosurgery. It is still controversial despite there are the indications of surgical evacuation. There are some described minimally invasive ICH evacuation techniques⁶⁻⁸. Minimally invasive techniques have some advantages of low cost, reduced brain trauma, fewer complication, low mortality and disability rate, short operative time, less infection rate and better curative effects^{6, 9, 10} compared to craniotomy¹¹. Craniotomy and DC have some advantages such as good view, immediate removal of hematoma. There are some limitations in DC surgery such as increased in operative time, chance of infection more and need of cranioplasty. Even though, this study is done to identify the role of

DC with duraplasty plus ICH evacuation for both traumatic and hypertensive deep seated BG ICH.

MATERIALS AND METHODS

We have retrospectively reviewed three cases for intracerebral hemorrhage who underwent decompressive craniectomy adding duraplasty with ICH evacuation from January 2019 to December 2010. These cases are as follows:

Case 1: 20 year /male presented in emergency department(ED) with an alleged history of road traffic accident (RTA), hit by truck while riding bike on road 4 hours prior to admission. When patient admitted in NICU, his GCS was 13/15(E4V3M6); pupil was B/L 2mm reactive and left sided weakness (both upper and lower limb- 1/5). GCS was dropped to 7/15(E1V1M5) on third day of admission. CT head was done and found increased in volume of right basal ganglia ICH with midline shift (**Figure 1.A**).Urgent craniotomy with ICH evacuation and duraplasty was done. Following surgery patient did not improve in GCS and B/L pupil became 5mm sluggish. Therefore, decompressive craniectomy was also done on 3rd day of craniotomy. Thereafter, improvement in GCS (15/15) and power (Right both UL/LL limb-5/5, left UL -3/5 and left LL-2/5) were noted. Repeat CT head was done (**Figure 1B**) and Patient discharged on 23rd day of second surgery.

Case 2: 54 year/female presented in ED with c/o left sided weakness (Left both UL and LL-1/5), altered in sensorium, vomiting and slurring of speech since 5days. Patient had history of hypertension (HTN) under irregular medication since 5 years. Her GCS was 12/15 (E4V2M6) and B/L pupil- 3mm reactive to light. Patient dropped in GCS (31V1M4) on second day of admission; and right pupil 3 mm non reactive to light and left pupil-2mm sluggish. Repeat CT head was done and found massive edema with increased in right basal ganglia ICH volume and midline shift (**Figure 2A**). Therefore urgent decompressive craniectomy with ICH evacuation and duraplasty was done (**Figure 2 B**). There was improvement in GCS (15/15) and power (Right both UL/LL -5/5, left UL -2/5 and left LL-2/5) after surgery. He discharged on 21st days of surgery.

Case 3: 40 year /male presented in ED with c/o left sided weakness (Left both UL and LL-1/5), vomiting and sudden loss of conscious; and had history of HTN under medication since 3year. GCS was 15/15and B/L pupil was 2mm reactive to light. On the third day of admission, his GCS dropped to 5/15 (E1V1M3) and B/L Pupil -3mm non reactive to light. Repeat CT head reported right basal ganglia ICH with volume increased, surrounding edema, and midline shift (**Figure 3A**). Decompressive craniectomy with duraplasty and ICH evacuation was done (**Figure 3.B**). Following surgery there was improvement in GCS (E4V5M6) and power (Right both UL/LL limb-5/5, left UL -3/5 and left LL-2/5) were noted. Patient discharged on 25th day of surgery.

DISCUSSION

Both HICH and TICH is major health burden with high morbidity, high mortality and higher rate of disability. HICH accounts for approximately 10-20 % of all stroke¹ and 8-15% in western countries like USA, UK and Australia¹².18-24% in Japan¹³ and Korea¹⁴; 18.8- 47.6% in china¹⁵, and 31.9% in Nepal¹⁶; and TICH accounts more than 40% all head injuries². Rincon reported that approximately 45% mortality may occur within 30day after ICH¹⁷. The mortality and disability rate of ICH are high, and most of the survivors have disabilities¹⁸.

Large ICH with peri-hematoma edema can produce severe elevation of intracranial pressure (ICP) leading to mass effect and midline shift. The surgical evacuation of large ICH with midline shift is main way to decrease mortality and prevent from further disability. The early surgical evacuation of large ICH (both TICH and HICH) is to prevent from secondary brain injury. The following mechanisms in brain after ICH which may cause secondary brain injury such as (a) contused or hemorrhagic brain does not recover therefore removal of ICH does not increase tissue loss, (b) Extravagated blood is believed to be neurotoxic leading secondary injury and brain edema¹⁹, (c) large TICH and HICH may be associated with ischemic penumbra of brain tissue that should be recovered, and (d) ICH may expand to some point which contribute to mass effect, midline shift^{19,20}, leading to further neurological deterioration and an increased risk of unfavorable outcome²¹. Therefore, removal of ICH in shortest time possible to reduce pain, reduce intracranial pressure and preserve neurological function to extreme range to set up favorable condition for the recovery of brain function²². Presently there are many surgical techniques for management of ICH; after all no optimum surgical techniques have been discussed. Open craniotomy is most commonly studied surgical approach in the clinical scenario. However, other approaches such as decompressive craniectomy ± hematoma drainage, image guided stereotactic endoscopic aspiration, and minimally invasive catheter evacuation followed by thrombolysis have been undertaken.

Minimal invasive endoscopic approach has some advantages such as (a) shorter operative time leading to less blood loss, (b) use of small bone window which minimizes direct exposure of brain to external environment and lessens the brain tissue injury, (c) provides direct vision of light which minimizes direct brain injury and high rate of evacuation of hematoma. However, endoscopic technique has some limitations such as (a) not suitable for cerebral hernia patients, (b) neurosurgeon should have experienced endoscopic application skills to handle three apparatus (suction, bipolar and endoscope) through small bone window, (c) Repeated cleaning should be done to avoid blood accumulation, so depth and angle of endoscope need to be adjusted time to time.

Decompressive craniectomy with hematoma evacuation for management of deep seated BG ICH is hot topic of debate and also no any proper study has been done. Decompressive craniectomy with or without hematoma evacuation may reduce mortality in patients with significant midline shift and large ICH, or in patients with refractory intracranial pressure²³. DC has some limitations such (a) prolonged operative time, (b) chance of high blood loss, (c) large bone flap need to be removed, (d) causes larger skin incision which takes long time to be recovered and increases chance of infection too, (e) exposes larger normal brain to external environment which maximizes surrounding normal brain tissue injury, and (f) need second operation for cranioplasty and gives extra burden of cost as well. However, DC has some advantages such as (a) provides good view of surgical field, (b) immediate removal of hematoma, (c) relaxation of edematous brain after durotomy and improvement in local blood circulation, (d) duraplasty also provides better expandable area for brain if the post operative brain swelling occurs. Alex H et al reported that additional ICH evacuation along with decompressive craniectomy for intracerebral hemorrhage does not seem to be beneficial²⁴. Similarly, a study done by Rasras S described there is no significant difference in outcome between with hematoma evacuation and without hematoma evacuation along with DC for intracerebral hemorrhage²⁵. In this paper, we attempted decompressive craniectomy with duraplasty and ICH evacuation for all three cases. All three patients had GCS <8 and midline shift with massive edema. We found improvement in GCS (15/15) and power as compared to previous state of surgery.

CONCLUSIONS

Decompressive craniectomy with duraplasty and ICH evacuation during management for both TICH and HICH is effective and safe approach; and has better outcome (GCS-15/15) in all three patients who had GCS < 8, BG ICH and midline shift at preoperative state. However, due to small number of patients in this case series, a larger sample for further study is still necessary.

ABBREVIATIONS

DC: Decompressive craniectomy, BG: Basal ganglia, ICH: Intracerebral hemorrhage, GCS: Glasgow coma scale, GOS: Glasgow outcome scale, HTN: Hypertension; HICH: Hypertensive intracerebral hemorrhage, TICH: Traumatic intracerebral hemorrhage

ACKNOWLEDGEMENT

None

AUTHOR'S CONTRIBUTIONS

Mohan Karki initiated, collected data and wrote manuscript. Yam Bdr. Roka was major contributor for revising the manuscript. All authors read and approved final manuscript.

FUNDING

Not applicable

CONFLICT OF INTERESTS

There is no conflict of interests

REFERENCES

1. Feign VL, Lawes CMM, Benneett DA, Barker-collo SL, Parag V. Worldwide stroke incidence and early case fatality reported in 56 population-based studies: a systematic review. *Lancet Neurol.* 2009; 8: 355-69.
2. Barba AG, Elise NR, Patrick MM, Andy U, Elaine MM, Lain RC et al. Surgical trail in traumatic intracerebral hemorrhage (STITCH(Trauma)): a study protocol for a randomized control trial. *Study Protocol.* 2012; 13:193.
3. Ariesen MJ, Claus SP, Rinkel GJE, Algra A. Risk factors for intracerebral hemorrhage in the general population: a systematic review. *Stroke.* 2003; 34:2060-5.
4. Yamada M. Cerebral angiopathy: emerging concepts. *J Stroke.* 2015; 17: 17-30.
5. Siddique MS, Gregson BA, Fernandes HM, Barnes J, Treadwell L, Wooldridge TD et al. Comparative study of traumatic and spontaneous intracerebral hemorrhage. *J Neurosurg.* 2002; 96:86-89.
6. Chao DY, Chen CC, Chhhang CS, Lee WY, Tso M. Endoscopic surgery for sponetaneous basal ganglia hemorrhage: Comparing endoscopic surgery, stereotactic aspiration , and craniotomy in non-comatose patients. *Surg Neurol.* 2006; 65:547-555.
7. Nishihara T, Morita A, Teraoka A, Kirino T. Endoscopic-guided removal of spontaneous intracerebral hemorrhage: Comparison with computer tomography –guided evacuation. *Childs Nerv Syst.* 2007; 23:677-683.
8. Sun G, Li X, Chen X, Zhang Y, Xu Z. Comparision of keyhole endoscopy and craniotomy for treatment of patients with hypertensive cerebral hemorrhage. *Medicine.* 2019; 98:2.
9. Nagasaka T, Tsugeno M, Ikeda H, Okamoto T, Inao S, Wakabayashi T. Early recovery and better evacuation rate in neuroendoscopic surgery for spontaneous intracerebral hemorrhage using a multifunctional cannula: Preliminary study in comparison with craniotomy. *J Cerebrovasc Dis.* 2011;20:208-13.
10. Broderick J, Connolly S, Feldmann E, Hanley D, Kase C, Krieger D et al. American Heart Association; American Stroke Association Stroke Council; High Blood Pressure Research Council; Quality of Care and Outcomes in Research Interdisciplinary Working Group.Guidlines for the management of spontaneous intracerebral hemorrhage in adults:2007 update: a guidelines from the American Heart Association/American Stroke Association Council, high blood pressure research

council, and the quality of care and outc. *Stroke*. 2008; 38:2001-3.

11. Yamashiro S, Hitoshi Y, Yoshida A et al. Effectiveness of endoscopic surgery for comatose patients with large supratentorial intracerebral hemorrhage. *Neurol Med Chir (Tokyo)*. 2015; 55:819-23.

12. Yamashiro S, Hitoshi Y, Yoshida A, Kuratasu J. Epidemiologic assessment of the role of blood pressure in stroke. The Framingham study. *JAMA*. 1970; 214:301-310.

13. Toyoda K. Epidemiology and registry studies of stroke in Japan. *J Stroke*. 2013; 15:21-26.

14. Hong KS, Bang OY, Kang DW, Yu KH, Bae HJ, Lee JS et al. Stroke statistics in korea: part I. Epidemiology and risk factors: a report from the Korean stroke society and clinical research centre for stroke. *J Stroke*. 2013; 15:2-20.

15. Liu M, Wu B, Wang WZ, Lee LM, Zhang SH, Kong LH. Stroke in china: epidemiology, prevention, and management strategies. *Lancet*. 2007; 6:456-64.

16. Devkota KC, Thapamagar SB, Malla S. Retrospective analysis of stroke and its risk factors at Nepal Medical College Teaching Hospital. *Nepal Med Coll J*. 2006; 8:269-75.

17. Rincon F, Mayer SA. Intracerebral hemorrhage: getting ready for effective treatments. *Curr Opin Neurol*. 2010; 23:59-64.

18. Krishnamurthi RV, Feigin VL, Forouzanfar MH. Global and regional burden of first-ever ischaemic and hemorrhagic stroke during 1990-2010: findings from the Global Burden of Diseases Study 2010. *Lancet Glob Health*. 2013; 1:259-81.

19. Xi G, Keep RF, Hoff JT. Mechanism of brain injury after intracerebral hemorrhage. *The Lancet Neurol*. 2006; 5:53-63.

20. Boto GR, Lobato RD, Rivas JJ, Gomez PA, de la Lama A, Lagares A. Basal ganglia hematoma in severely head injured patients: clinico-radiological analysis of 37 cases. *J Neurosurg*. 2001; 94:224-232.

21. Dowlatshahi D, Demchuk AM, Flaherty ML, Ali M, Lyden PL, Smith EE. Defining hematoma expansion in intracerebral hemorrhage: relationship with patient outcomes. *Neurology*. 2011; 76:1238-44.

22. Li N, Liu YF, Ma L et al. Association of molecular markers with perihematomal edema and clinical outcomes in intracerebral hemorrhage. *Stroke*. 2013; 44:658-63.

23. Li N, Liu YF, Ma L, Worthmann H, Wang YL, Wang YJ, et al. Guidelines for the management of spontaneous intracerebral hemorrhage: a guideline for healthcare professionals from the American Heart Association/American Stroke Association. *Stroke*. 2015; 46:2032-60.

24. Alexis H, Patrick S, Inja I, Valeri B, Hartmut V, Erdem G. Decompressive craniectomy for intracerebral hematoma: the influence of additional hematoma evacuation. *Neurosurg Rev*. 2018; 41:649-654.

25. Rasras S, Safari H, Zeinali M, Jahannngiri M. Decompressive craniectomy without clot

evacuation in supratentorial deep-seated intracerebral hemorrhage. *Clin Neurol Neurosurg*. 2018; 174:1-6.

FIGURE LEGENDS

Figure 1. Preoperative axial CT head with large right BG ICH with midline shift (A) and Post operative axial CT head with complete evacuation of ICH and resolving edema (B).

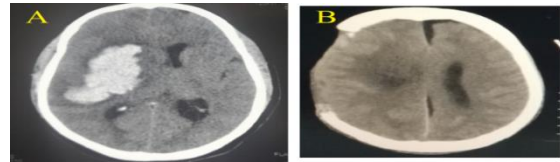


Figure 2. Preoperative axial CT head with right BG ICH with midline shift (A) and Post operative axial CT head with complete evacuation of ICH and resolved edema (B).

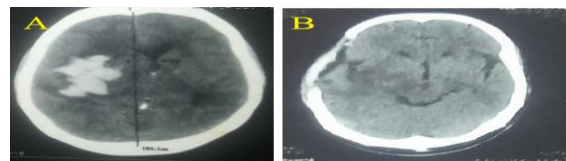


Figure 3. Preoperative axial CT head with right BG ICH with midline shift (A) and Post operative axial CT head with complete evacuation of ICH and resolved edema (B).

